Table S1. Detailed biological, epidemiological and pathological data of examined Stejneger's beaked whales.

Case No.	Museum ID	Sex	BL	Age class	Age	BC	DC	Coordinates	Date Found	AA	RC	Histopathologic findings other than AA and RC
1	M33615	M	191.0	Newborn		Poor	2	37.883N, 138.283E	4/10/2004	−	−	Fetal distress (marked amniotic fluid aspiration)
2	M34033	M	242.0	Calf		Poor	2	38.016N, 139.250E	6/7/2005	−	−	Focal renal fibrosis, mild
3	M31328	F	316.0	Juvenile		Good	2	39.183N, 139.917E	1/28/1997	−	−	Pulmonary and marginal lymph node mycosis, severe
4	M54931	M	389.0	Juvenile		Fair	2	36.838N, 137.005E	4/17/2017	+	+	Cardiomyocyte necrosis, mild; dermatitis, severe
5	M54994[a]	M	410.0	Juvenile		Good	2	43.324N, 145.327E	7/21/2017	−	+	Myocarditis, moderate
6	M32442	M	446.0	Adult		Good	2	41.083N, 140.317E	2/28/1999	+	+	
7	M42578	M	446.0	Adult		Poor	2	35.500N, 133.267E	3/25/2014	−	+	Cardiomyocyte hypertrophy, mild; intracardiomyocyte polyglucosan body deposition, mild; cardiac lipofuscinosis, mild
8	M32507	M	446.0	Adult	15.5[e]	Poor	2	38.583N, 139.567E	10/20/1998	−	+	Thyroglossal cyst
9	M55029[a]	M	448.0+[d]	Adult		Good	3	43.944N, 141.633E	1/11/2018	+	+	Cerebellar polyglucosan body deposition, moderate
10	M29880[b]	F	454.0	Adult		Poor	2	37.175N, 138.234E	5/5/1994	+	+	Pulmonary mycosis, severe; hepatic biliary proliferation, mild
11	M32544	M	456.0	Adult		Good	2	41.017N, 140.317E	2/2/2000	+	+	
12	M34165	M	458.5	Adult		Poor	2	39.650N, 140.067E	4/26/2006	−	+	Cardiomyocyte hypertrophy, mild; cardiomyocyte contraction band necrosis, mild; intracardiomyocyte polyglucosan body deposition, mild; cardiac lipofuscinosis, mild
13	M33614	M	460.0	Adult		Poor	3	35.616N, 135.917E	4/8/2004	−	+	Systemic lymphoid depletion, moderate
14	M32762	M	462.0	Adult		Poor	2	33.800N, 130.450E	2/20/2002	−	+	Balanitis, moderate
15	M35059	F	466.3	Adult		Fair	2	40.267N, 140.017E	2/24/2008	+	+	Bronchopneumonia, severe; intracardiomyocyte polyglucosan body deposition, moderate; cardiac lipofuscinosis, mild
16	M32441	M	471.0	Adult		Fair	3	37.167N, 138.083E	2/15/1999	−	+	Verrucous endocarditis, severe; gastric ulcer, moderate
17	M32426	F	473.0	Adult		Poor	2	41.733N, 140.583E	11/24/1998	−	+	Hepatic biliary proliferation, mild
18	M34257	M	475.0	Adult		Good	2	37.467N, 137.083E	4/5/2007	−	+	
19	M32477	F	476.0	Adult		Fair	3	38.750N, 139.733E	2/25/1999	+	+	
20	M35060	M	479.0	Adult		Good	2	45.445N, 141.653E	2/27/2008	−	+	
21	M33770	F	480.0	Adult		Fair	2	37.517N, 137.300E	3/23/2005	−	+	Enteritis, moderate; gastritis, moderate; renal infarction
22	M33433	F	481.0	Adult		Poor	2	36.516N, 136.517E	3/25/2003	+	+	
23	M36241	F	482.0	Adult		Poor	2	39.083N, 139.867E	3/11/2010	−	+	Focal adrenal hematoma; endometritis, mild; cardiomyocyte hypertrophy, mild; intracardiomyocyte polyglucosan body deposition, mild
24	M33566	F	485.0	Adult		Good	3	44.367N, 141.683E	11/9/2003	+	+	
25	M32561	M	485.0	Adult		Poor	2	33.933N, 130.733E	2/18/2000	−	+	Systemic lymphoid depletion, severe; interstitial pneumonia, moderate; hepatic biliary proliferation, mild
26	M34024	F	487.5	Adult		Fair	2	38.267N, 139.450E	5/2/2005	−	+	
27	M32703	M	490.0	Adult		Good	2	41.038N, 140.322E	3/27/2001	−	+	Gastritis, severe
28	M35080	F	492.0	Adult		Poor	2	37.400N, 137.250E	3/24/2008	−	+	Bronchitis, moderate; hepatic biliary proliferation, mild
29	M32613	M	493.0	Adult		Fair	3	45.449N, 141.644E	12/11/2000	−	+	Focal adrenal hematoma
30	M54943[a]	F	495.5	Adult		Good	2	41.770N, 140.744E	5/11/2017	+	+	Cerebellar polyglucosan body deposition, moderate; cardiac lipofuscinosis, mild
31	M32616	F	498.0	Adult		Fair	2	41.034N, 140.322E	1/19/2001	−	+	Bronchopneumonia, moderate; hepatic abscess, mild
32	M32510[c]	M	498.0	Adult	30[e]	Fair	2	38.633N, 139.600E	6/20/1999	+	+	
33	M32985	F	503.0	Adult		Fair	2	37.300N, 137.133E	4/29/2002	−	+	
34	M32564[c]	F	520.0	Adult		Poor	3	41.850N, 140.133E	3/6/2000	+	+	Focal hepatic fibrosis, severe; cardiac lipofuscinosis, mild
35	M42042	F	524.5	Adult		Fair	2	41.463N, 140.027E	1/5/2013	−	+	Hepatic biliary proliferation, moderate

Abbreviations: F, female; M, male; BL, body length (cm); BC, body condition; DC, decomposition code; AA, systemic amyloid A amyloidosis; RC, renal crassicaudiasis.

[a,b,c]Previously published cases of amyloidosis.

[a]Nakagun S, Watanabe K, Matsuishi T, Kobayashi M, Kobayashi Y. Surveillance of Amyloidosis in Stranded and Bycaught Cetaceans Off Hokkaido, Japan. *J Vet Med Sci*. 2019;81(6):897–902.

[b]Shindo J, Yamato A. Pathology of Stenjengeris beaked whale Mesoplodon stejnegeri stranded at Johetsu-city, Niigata-prefecture. *Nihonkai Cetol.* 1995;5:27–29. (in Japanese)

[c]Tajima Y, Shimada A, Yamada T, Cowan DF. Amyloidosis in two Stejneger's beaked whales (*Mesoplodon stejnegeri*) stranded at the Sea of Japan. *J Zoo Wildl Med.* 2007;38(1):108–113.

[d]Maxilla was broken and an accurate measurement was unattainable.

[e]Previously determined through counting the number of growth layers. Arai K, Yamada TK, Takano Y. Age estimation of male Stejneger's beaked whales (*Mesoplodon stejnegeri*) based on counting of growth layers in tooth cementum. *Mamm Study.* 2004;29(2):125–136.

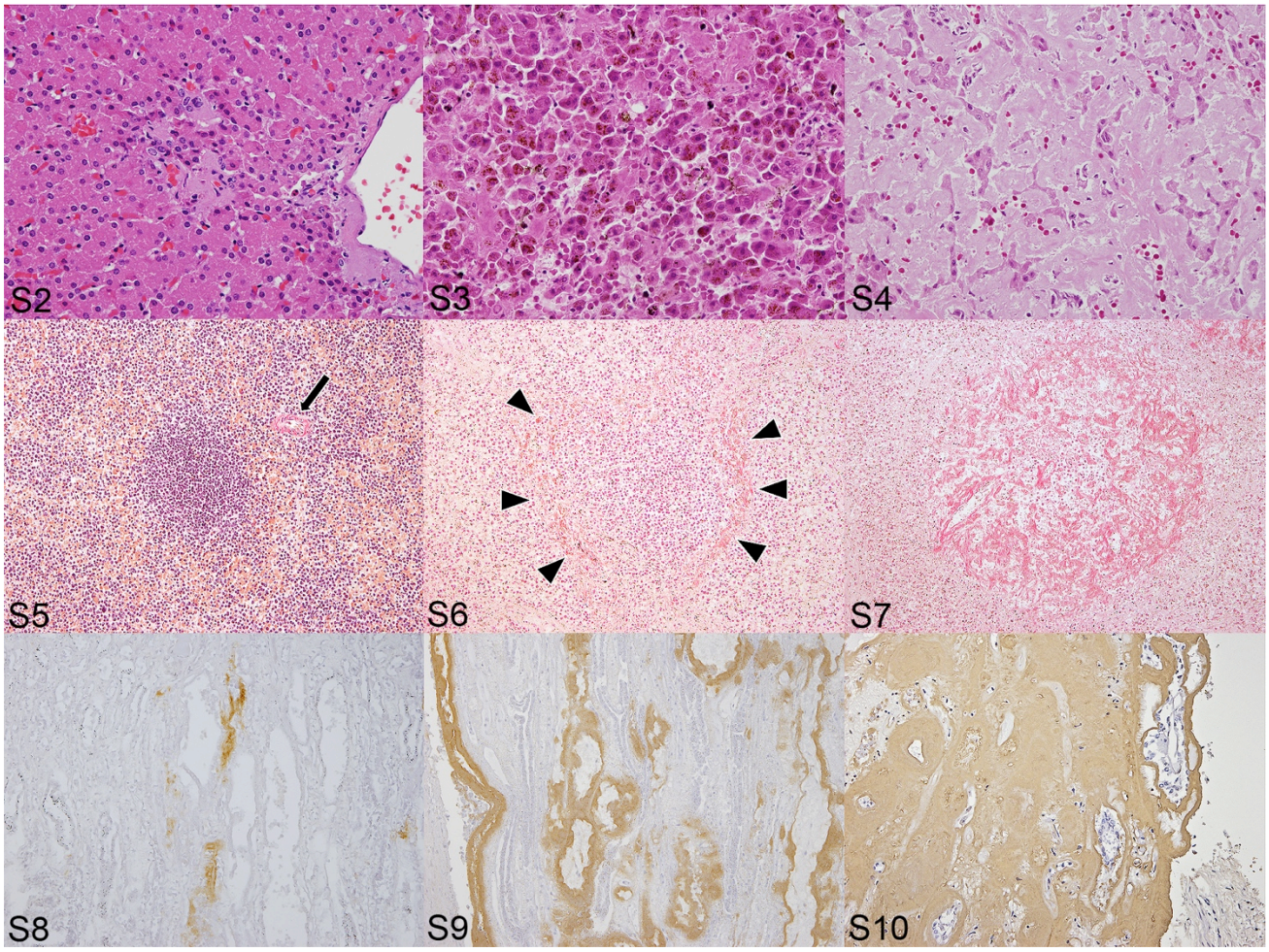

Figures S2–S10. Systemic amyloid A amyloidosis, Stejneger's beaked whale. **Figures S2–S4.** Liver. Mild (S2; Case No. 4), moderate (S3; Case No. 15) and severe (S4; Case No. 32) amyloid deposits with varying degrees of tissue architecture distortion including compression and loss of hepatocytes. Hematoxylin and eosin. **Figures S5–S7.** Spleen. Amyloid deposits are localized within arteriolar walls (arrow) in mild cases (S5; Case No. 4), whereas, moderate (S6; Case No. 22) and severe (S7; Case No. 10) cases have deposits within vessel walls as well as around (arrowheads) or within splenic follicles. Congo red. **Figures S8–S10.** Kidney. Mild amyloid aggregates in the medullary interstitium (S8; Case No. 22). Moderate (S9; Case No. 24) and severe (S10; Case No. 30) cases are with prominent deposits expanding the medullary interstitium, especially in the papilla. Immunohistochemistry for anti-amyloid A.

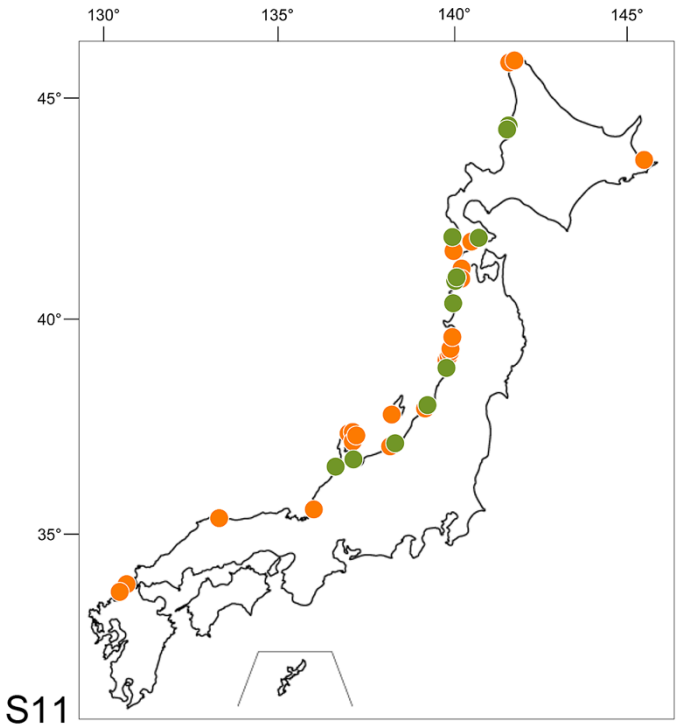

Figure S11. Stranding sites of examined Stejneger's beaked whales, with green circles indicating individuals with systemic amyloid A amyloidosis and orange circles indicating individuals without amyloidosis.

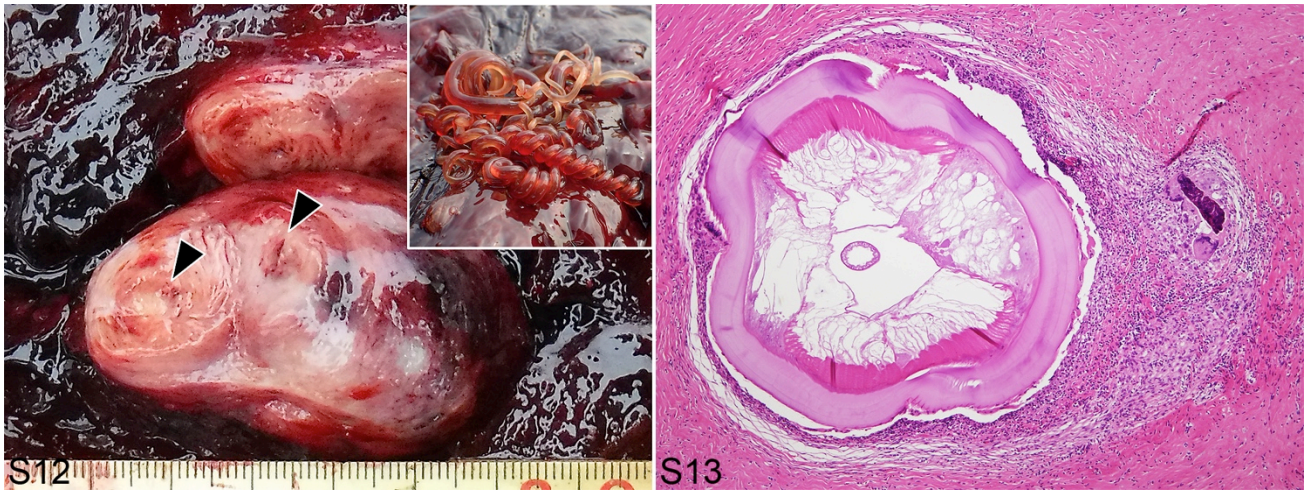

Figures S12–S13. Crassicaudiasis, kidney, Stejneger's beaked whale. **Figure S12.** Case No. 5. A large, 5 × 3 × 4 cm granuloma is formed within the renal parenchyma with nematodes embedded within (arrowheads). Inset shows gross morphology of the nematodes. **Figure S13.** Case No. 7. Histopathology reveals a nematode with a characteristic, thick cuticle layer in the center of the granuloma. Hematoxylin and eosin.

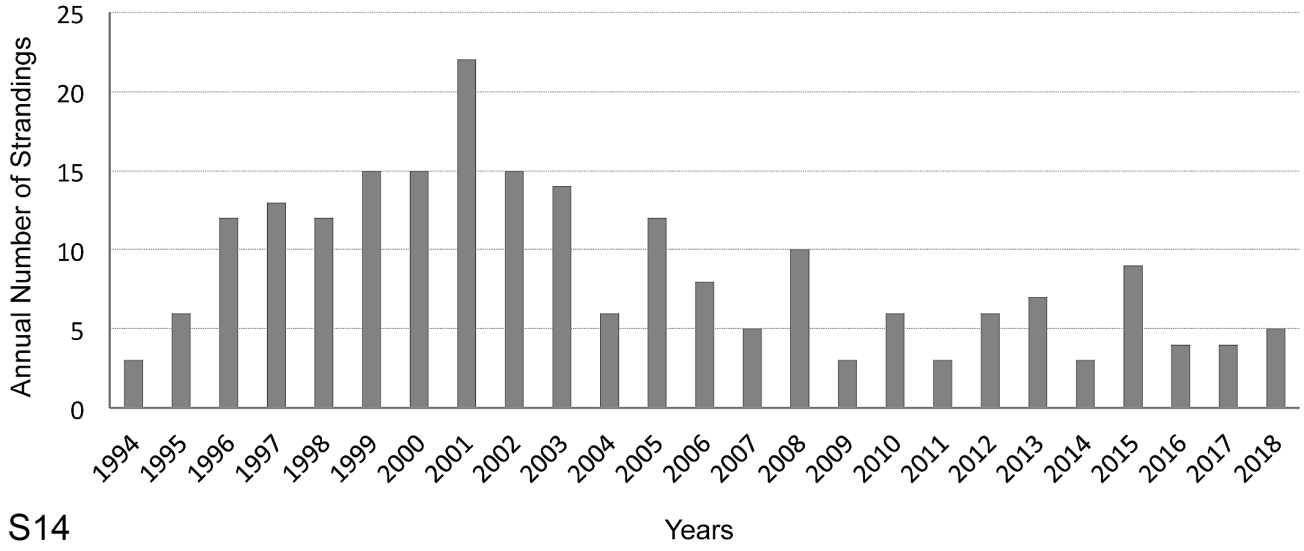

S14

Figure S14. Annual range of Stejneger's beaked whale strandings in Japan between 1994 and 2018.