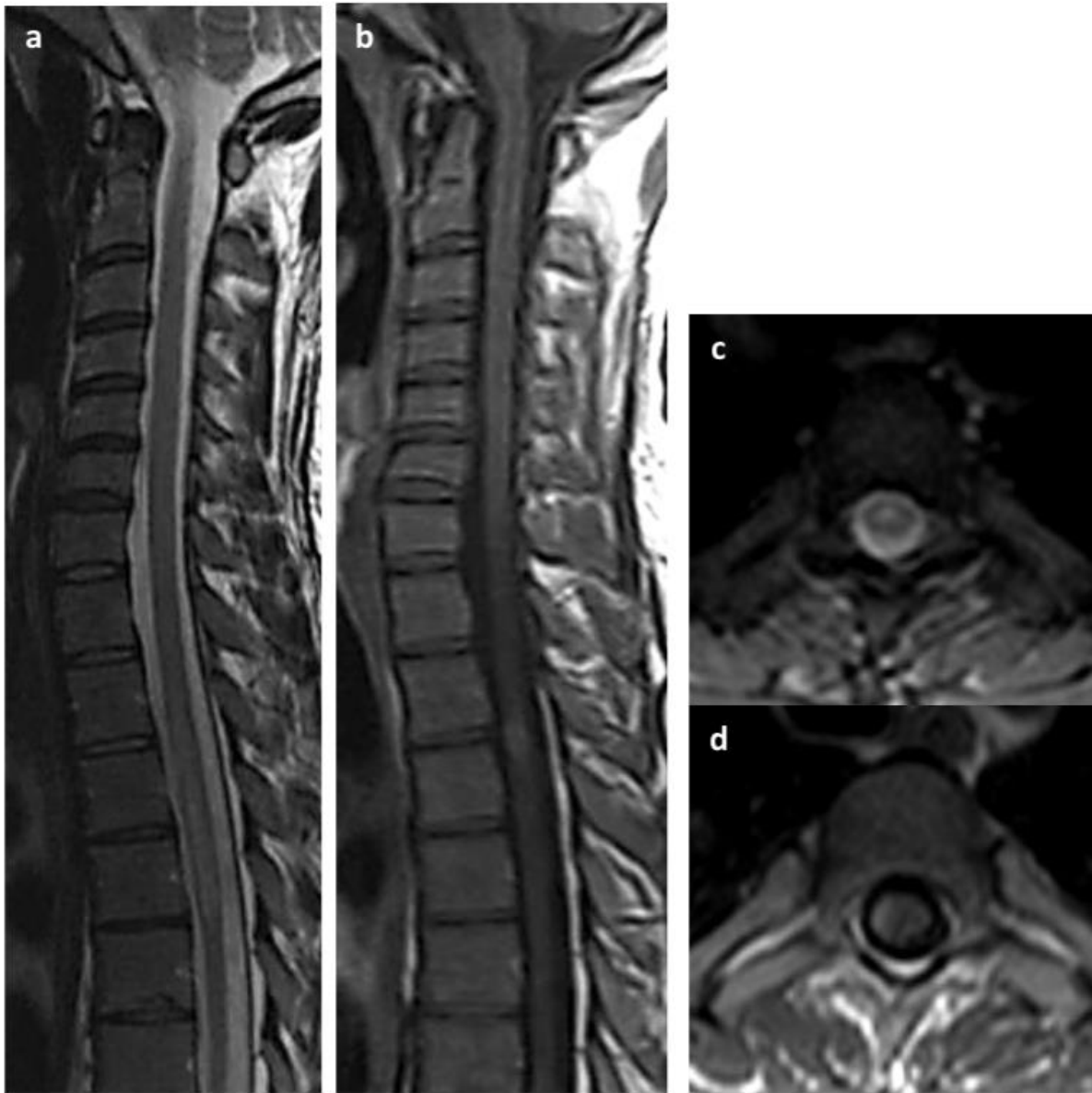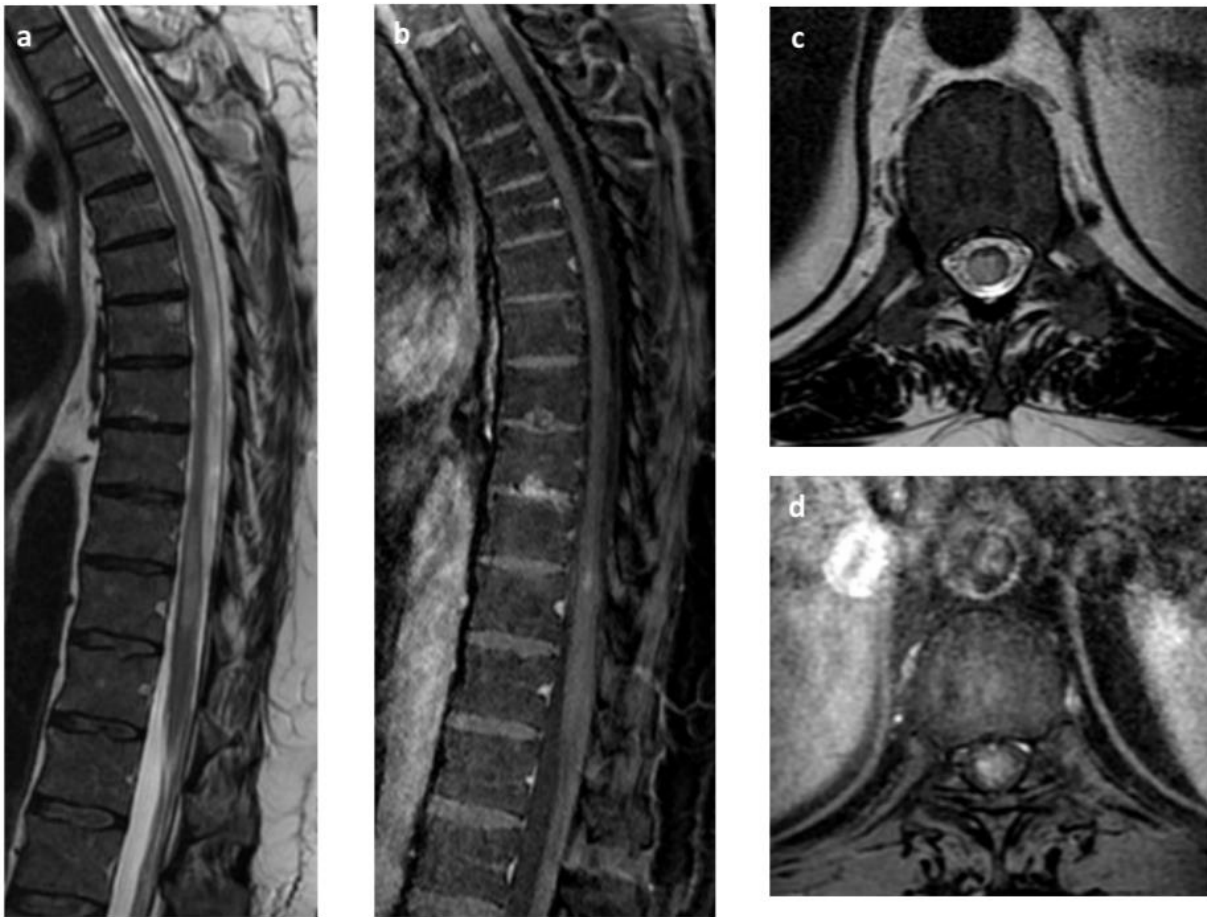


### Supplement Figures



SUPPLEMENTAL FIGURE 1 Dorsal spine images from a confirmed case of toxocara myelitis to compare to images from our illustrative case. 36 year old man with a 9 months history of paresthesia (sensory level at T4) and dysesthesia in bilateral lower extremities and urinary intermittency.

Sagittal T2 weighted images of the thoracic spine showing enlarged cord with high signal intensity at T2-T4 level (a) with focal nodular enhancement following contrast administration (b). Axial images demonstrating the signal abnormality in the center and laterally in the cord (c) with a peripherally located focal nodular enhancement along the right aspect of the lesion (d).



SUPPLEMENTAL FIGURE 2 Dorsal spine images from a confirmed case of toxocara myelitis to compare to images from our illustrative case. 48 year old man with a 3 months history of right lower extremity paresthesia, urinary urgency, and constipation.

Sagittal T2 weighted images of the thoracic spine showing enlarged cord with long segment high signal intensity at T11-T12 level (a) with focal nodular enhancement following contrast administration (b). Axial images demonstrating the signal abnormality in the center and periphery of the cord (c) with a peripherally located focal nodular enhancement along the right lateral aspect of the lesion (d).