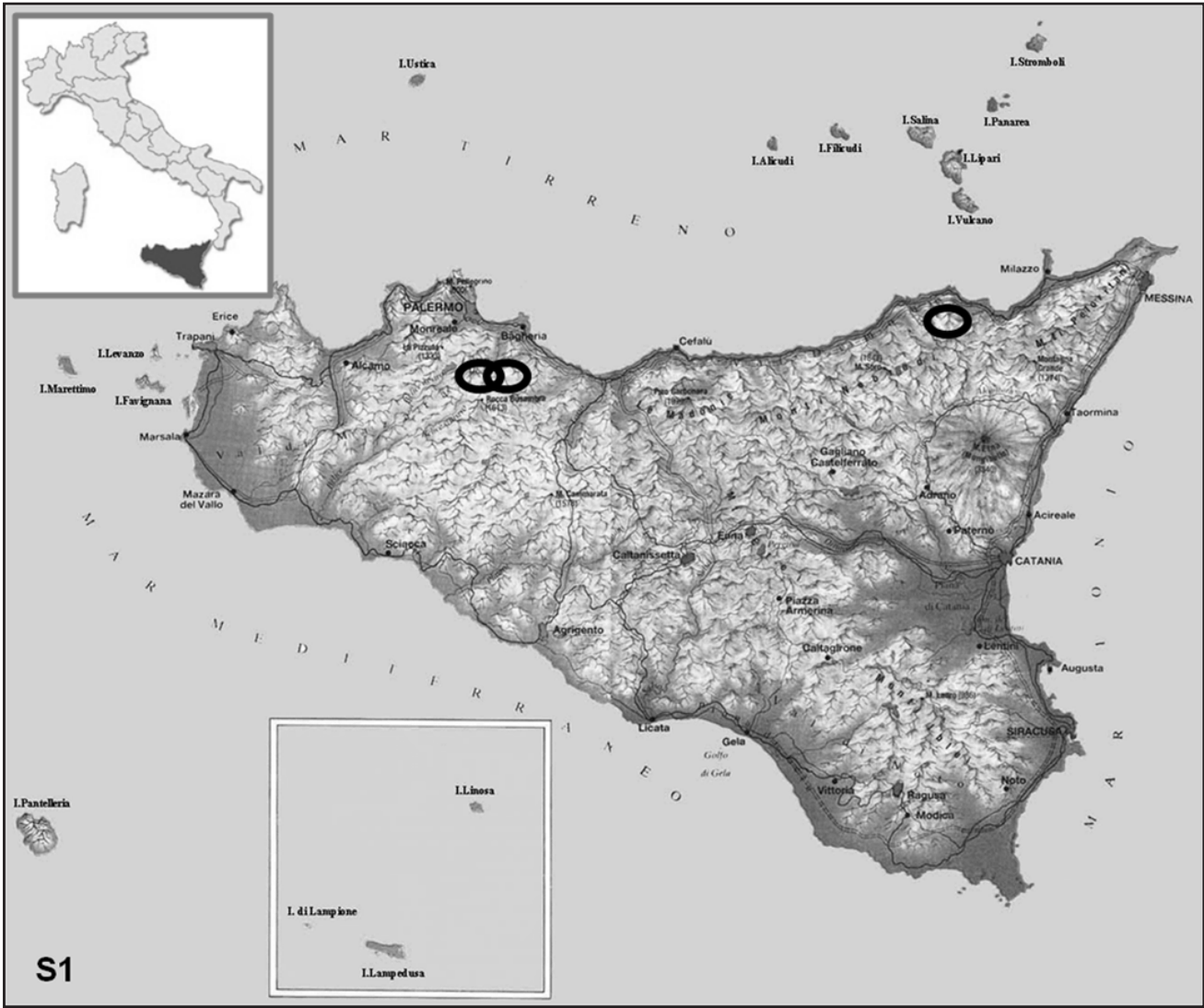


Veterinary Pathology: Supplemental Materials.
Mignacca et al. *Cistus salviifolius* toxicity in cattle.



Supplemental Figure S1. Geographical areas where the three herds(black circles) are located (North of Sicily, insular region of southern Italy).

Supplemental Table S1: Blood sampling and pathological exams performed.

		Group 1	Group 2	Group 3	Healthy animals
Blood samples	Farm A	0	3	3	2
	Farm B	3	3	2	2
	Farm C	0	2	1	2
Pathological exams	Farm A	0	1	0	
	Farm B	0	2	0	