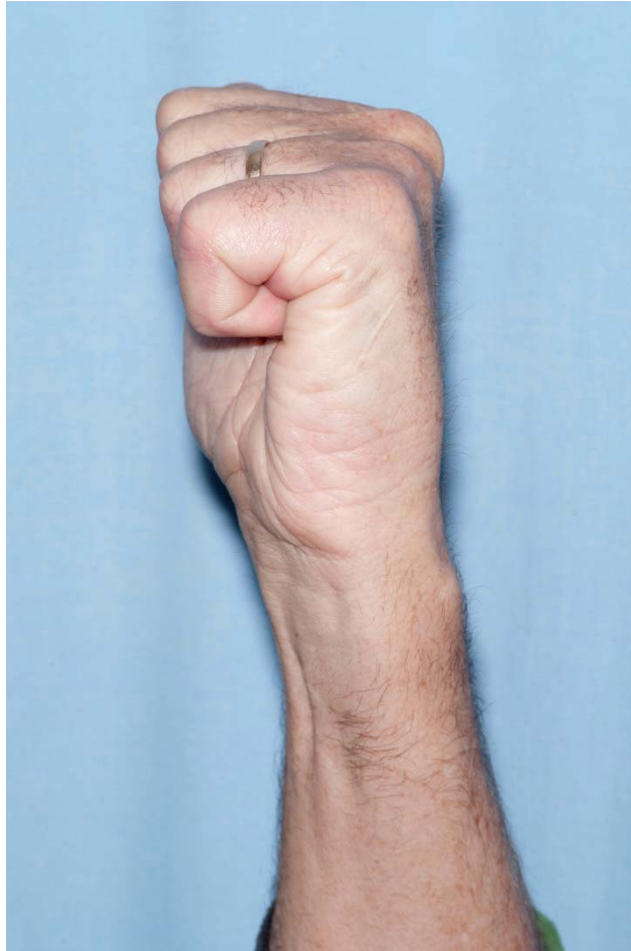



Government of **Western Australia**
North Metropolitan Health Service
Sir Charles Gairdner Osborne Park Health Care Group

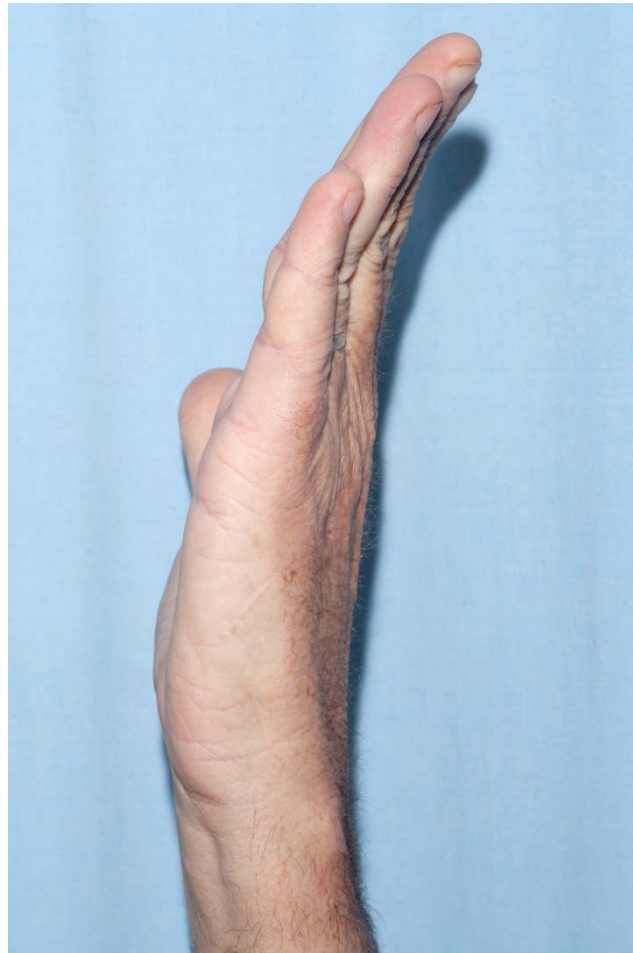


Case 1 56 year old man undergoing this treatment (Figure 2) 8 week flexion



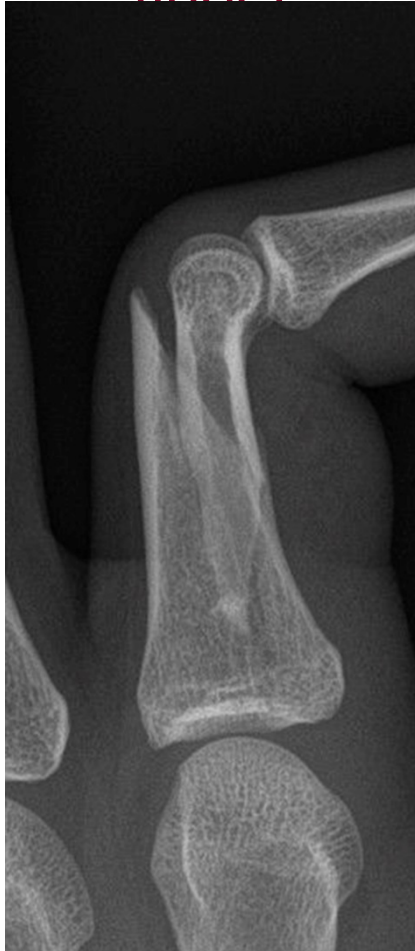Case 1

8 week extension



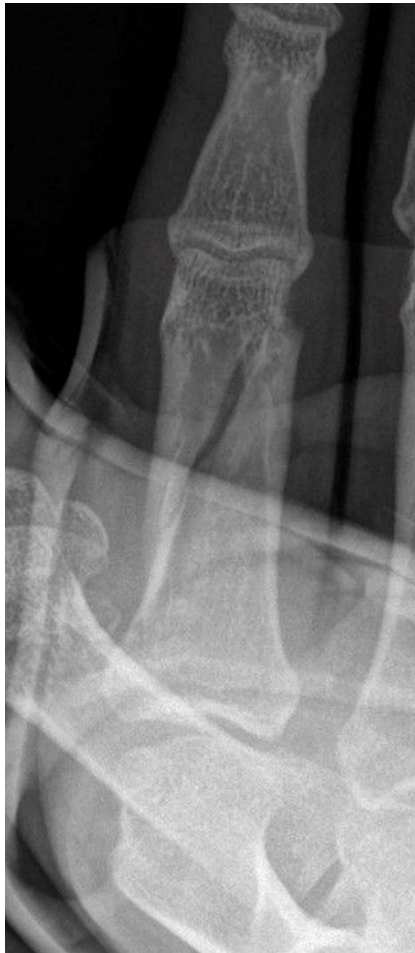Case 2

17 year old male, initial presentation, AP view, right index
finger



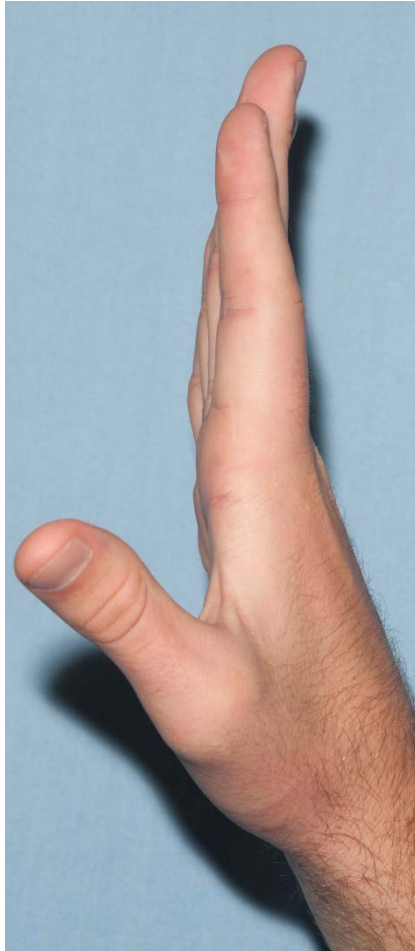
Case 2

2 weeks post reduction, PA view



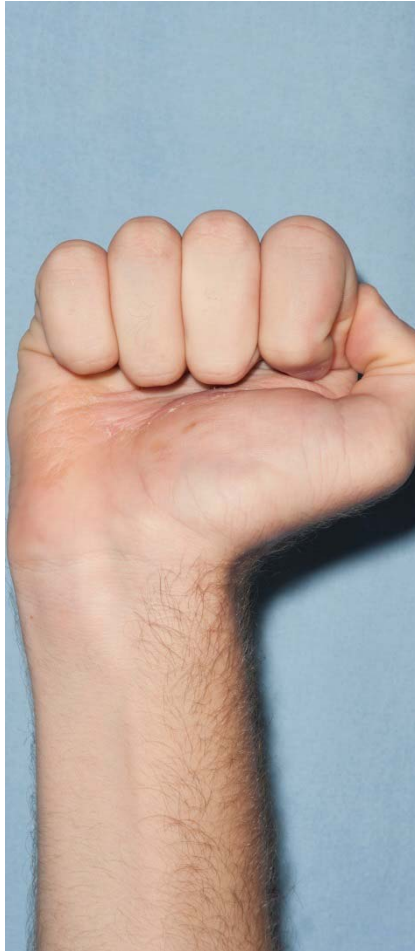Case 2

4 week extension



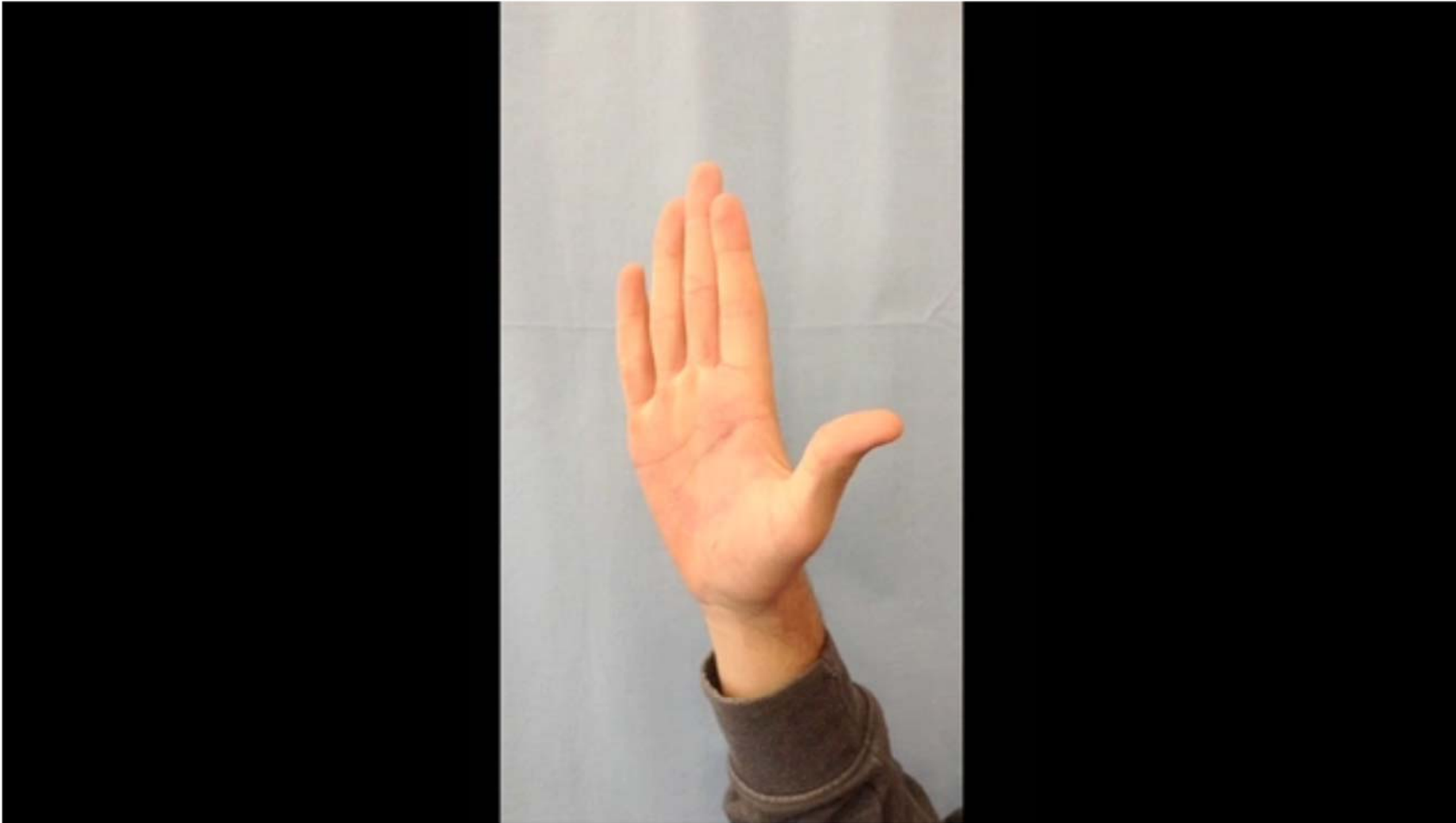Case 2

4 week flexion



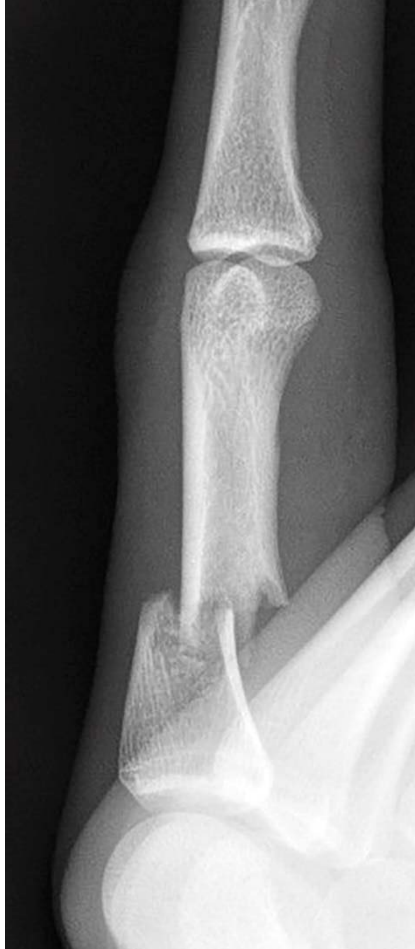Case 2

4 week AROM: video



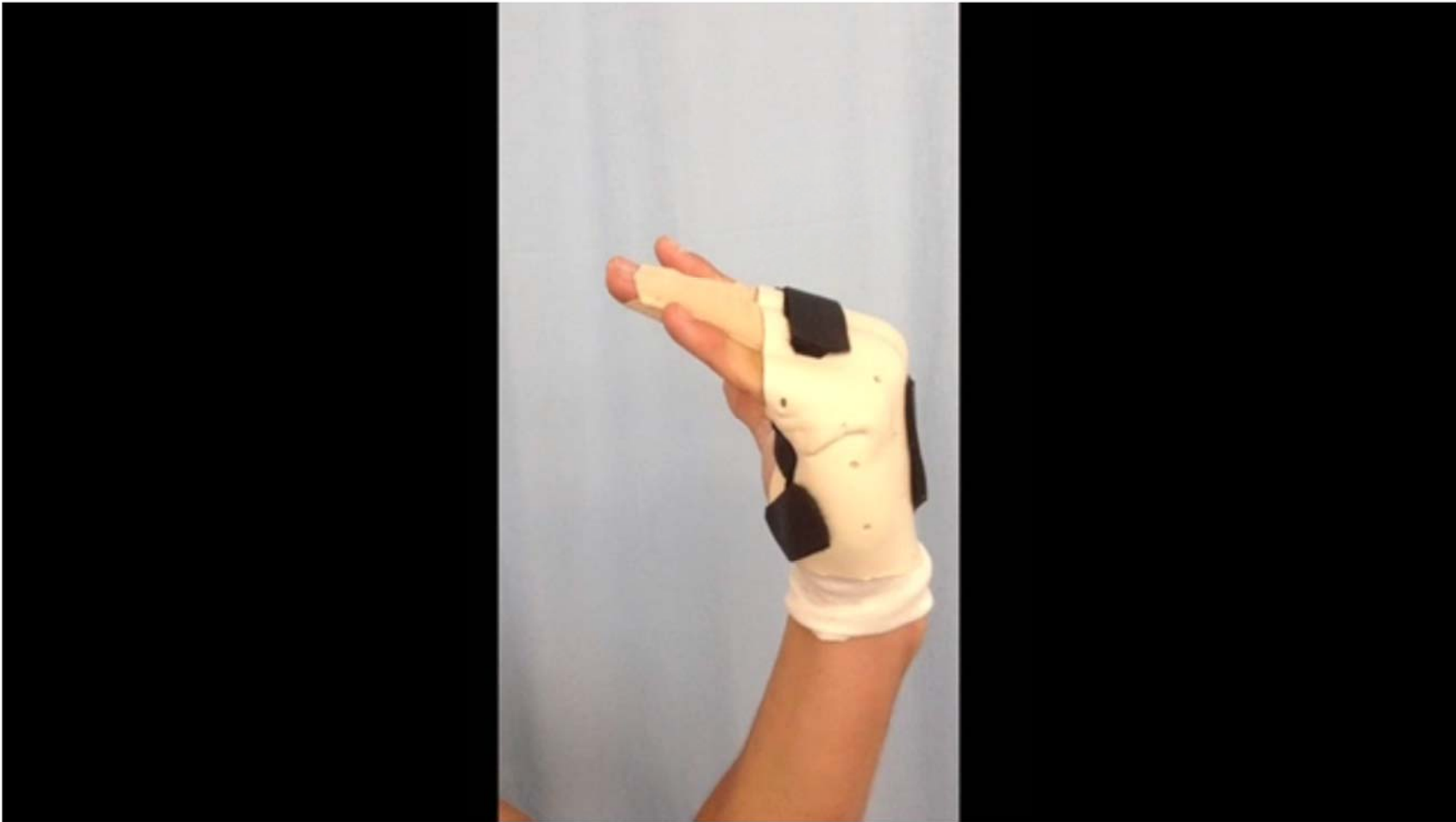Case 3

19 year old male, initial presentation, lateral view, left
middle finger



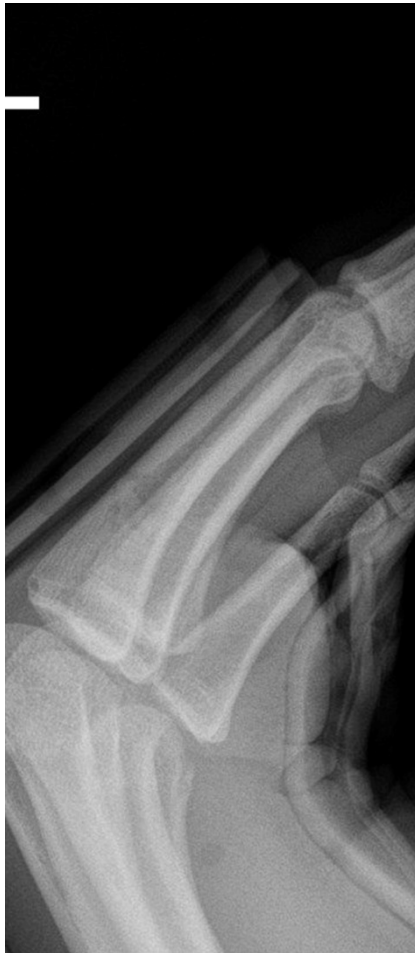Case 3

Post reduction, immediate AROM in splint: video



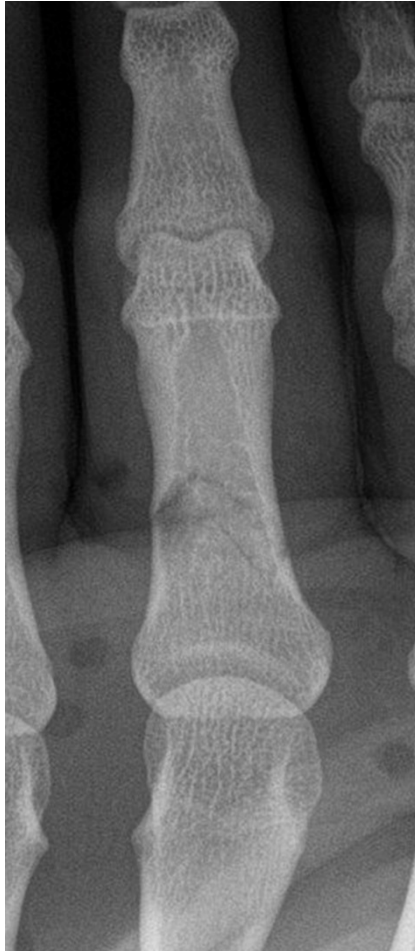Case 3

1 week post reduction, lateral view



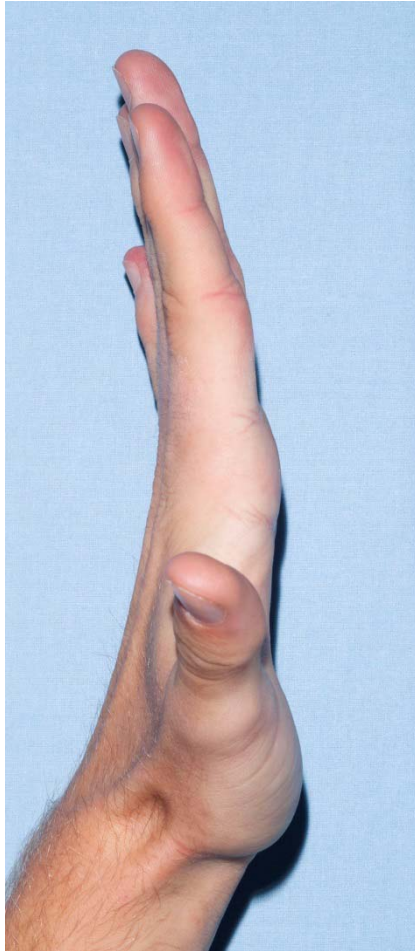
Case 3

1 week post reduction, PA view



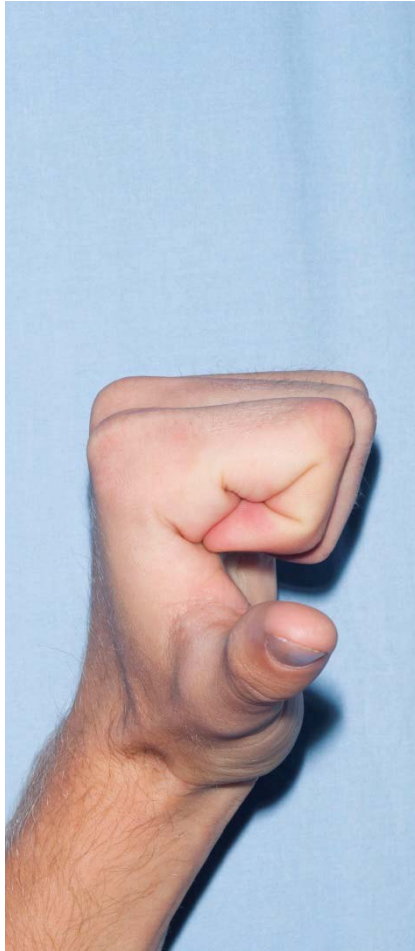
Case 3

4 week extension



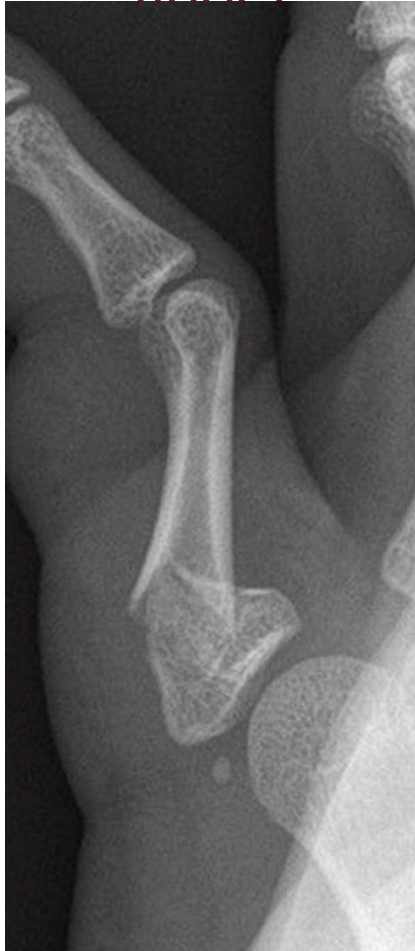Case 3

4 week flexion



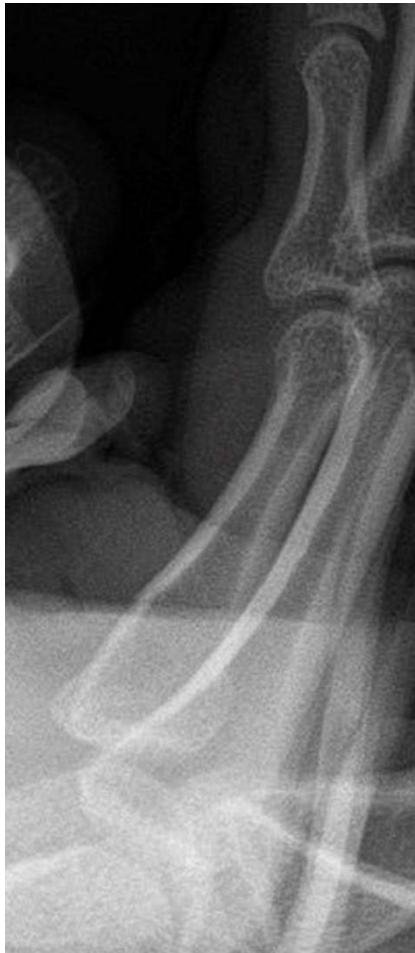Case 4

17 year old male, initial presentation, lateral view, right little
finger



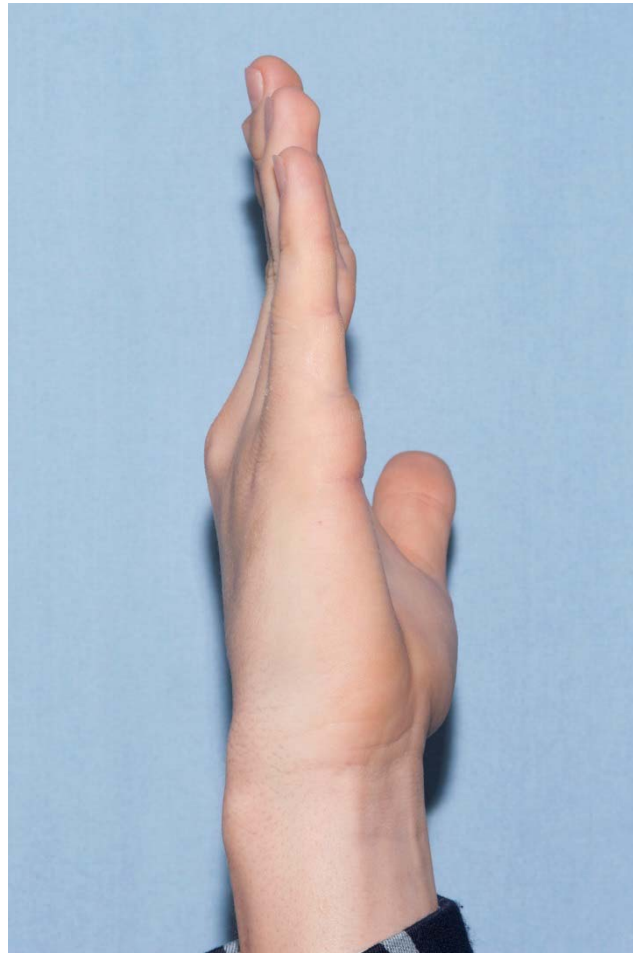
Case 4

1 week post reduction, lateral view




Case 4

4 week extension



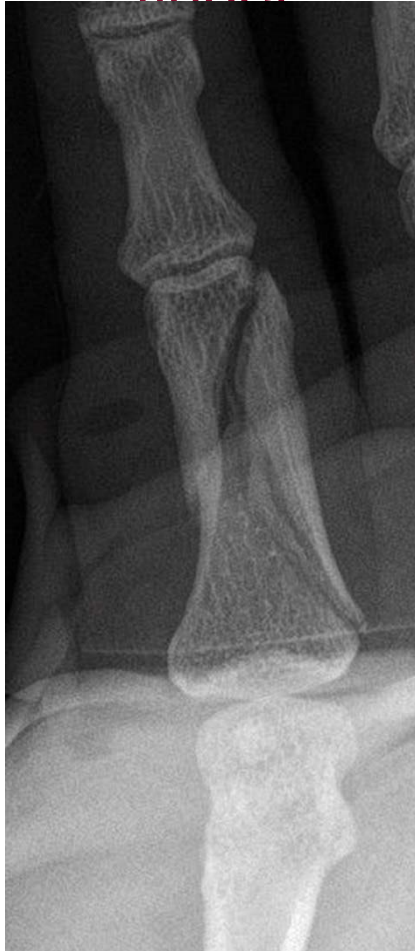Case 4

4 week flexion



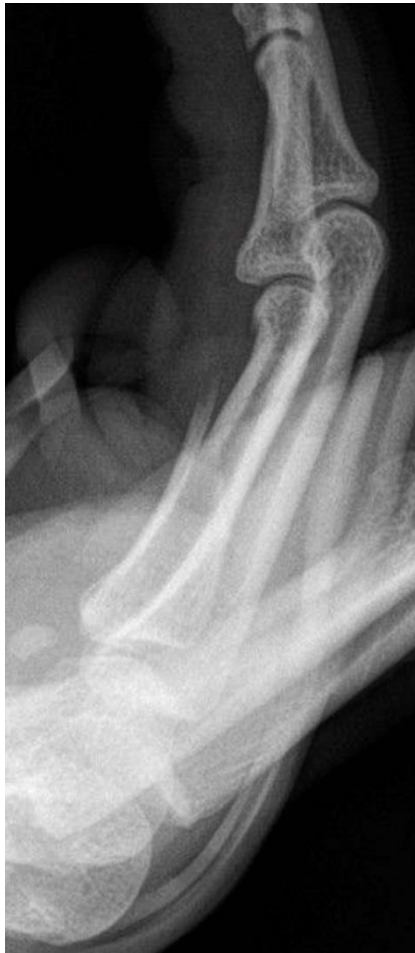Case 5

50 year old male, 1 week post splint, AP view, right little
finger



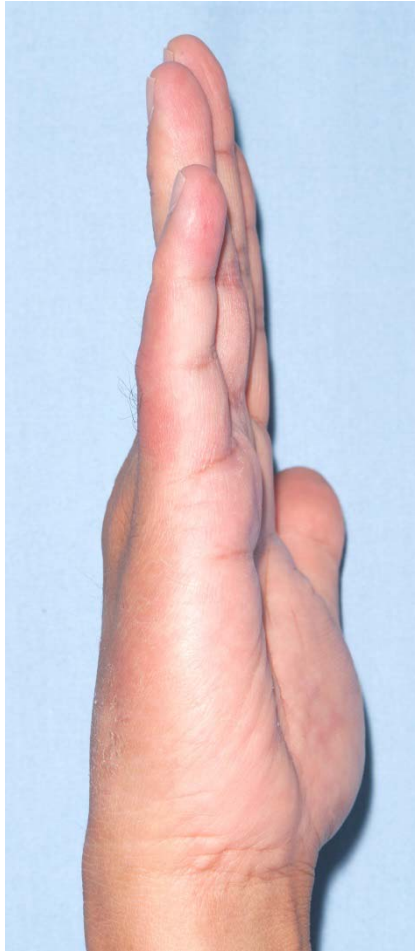
Case 5

1 week post splint, lateral view



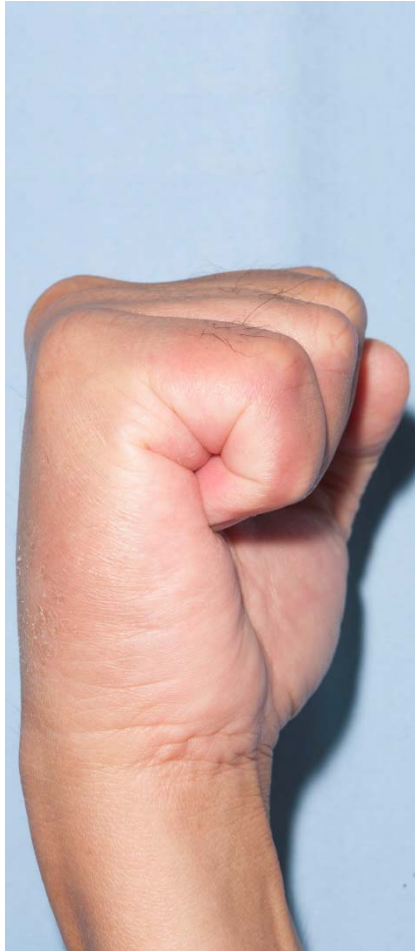Case 5

6 week extension



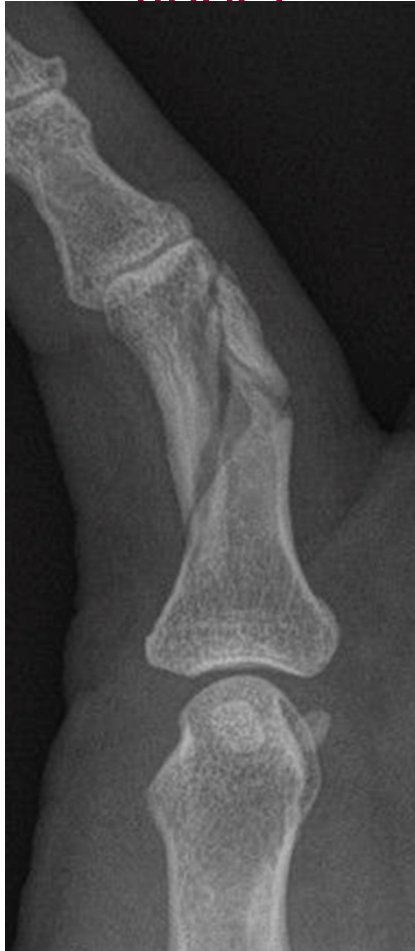Case 5

6 week flexion



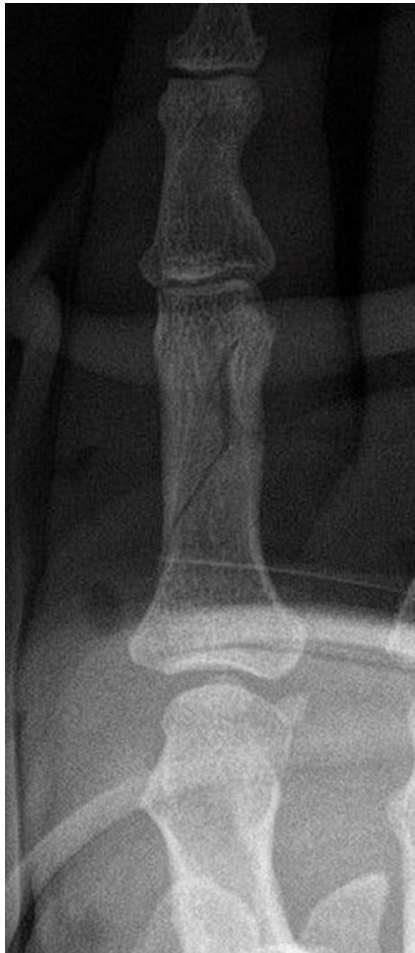Case 6

51 year old female, initial presentation, PA view, left little
finger



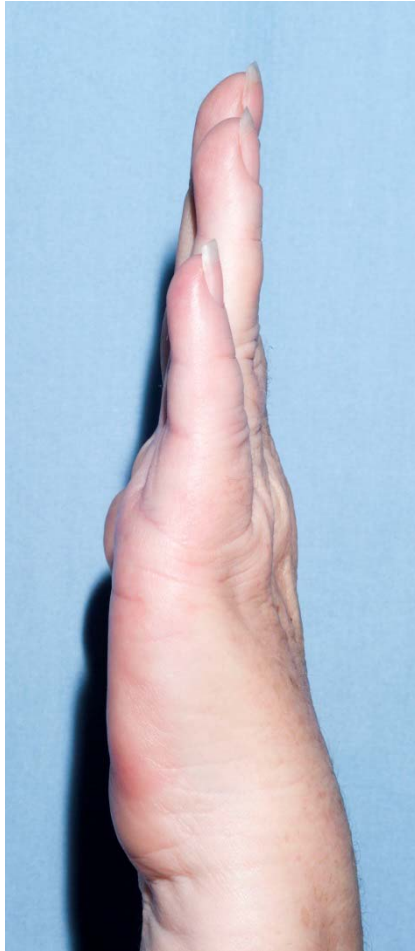Case 6

Post reduction, PA view



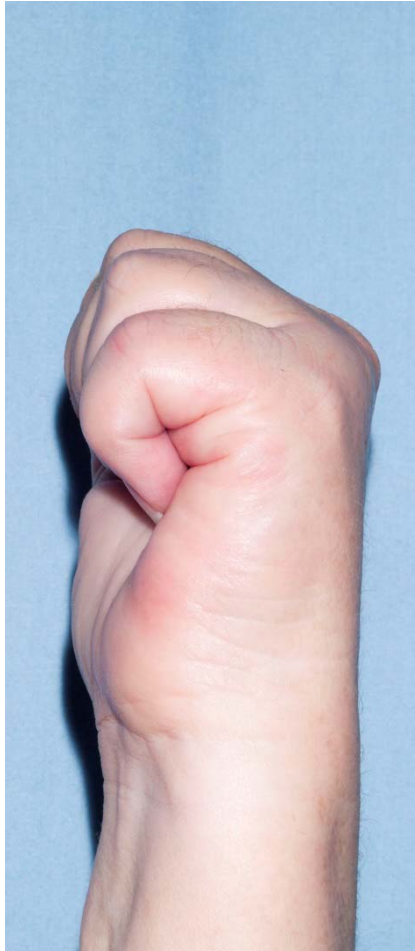Case 6

6 week extension



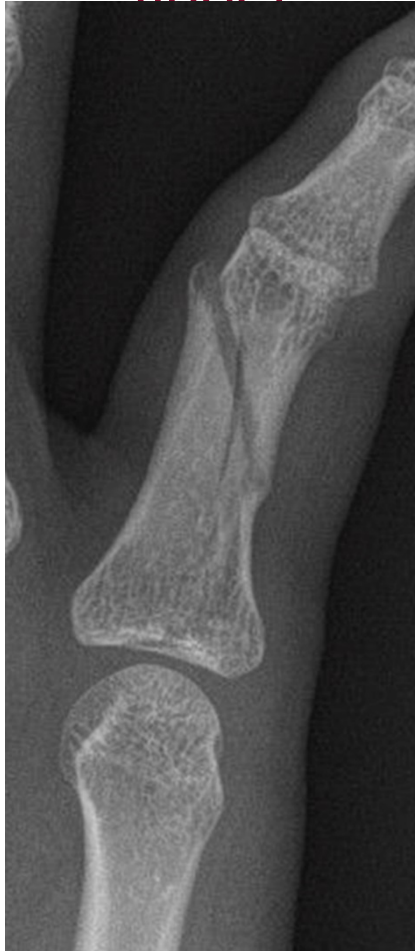Case 6

6 week flexion



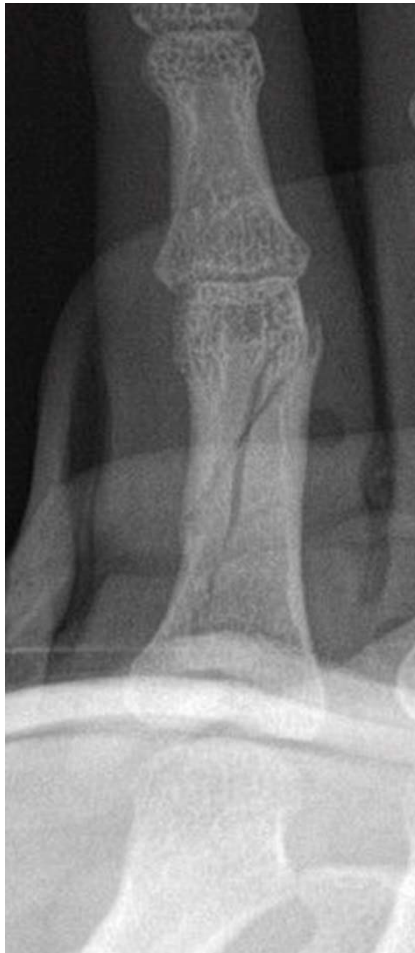Case 7

16 year old female, initial presentation, PA view, right little
finger



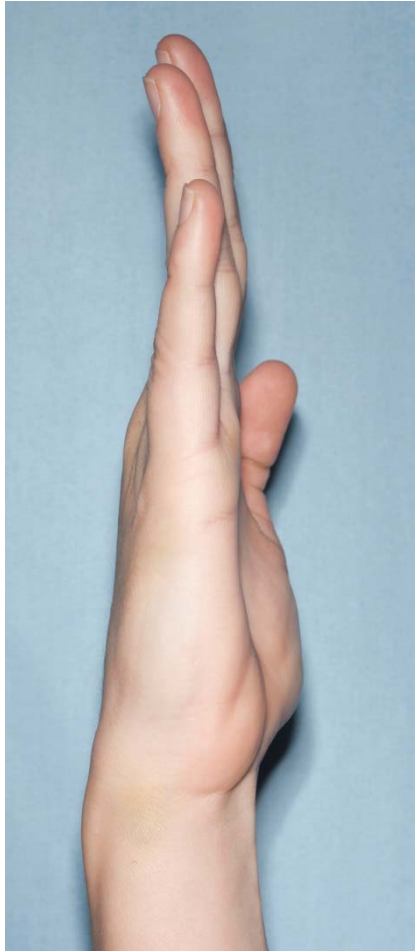
Case 7

1 week post reduction, AP view



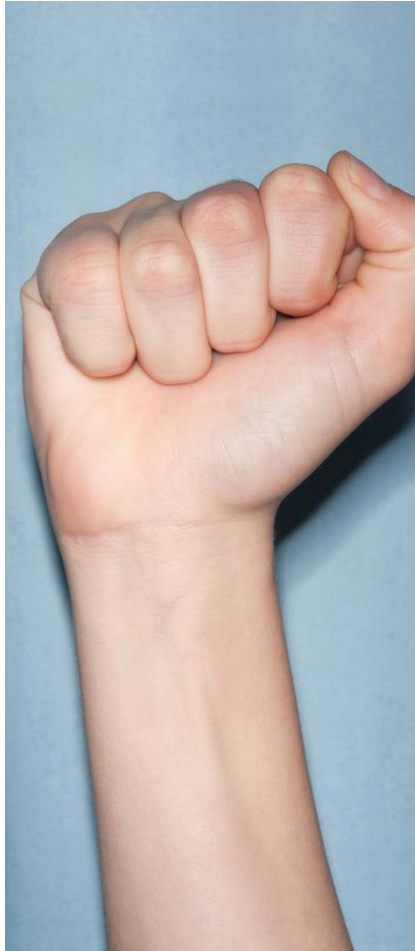Case 7

4 week extension



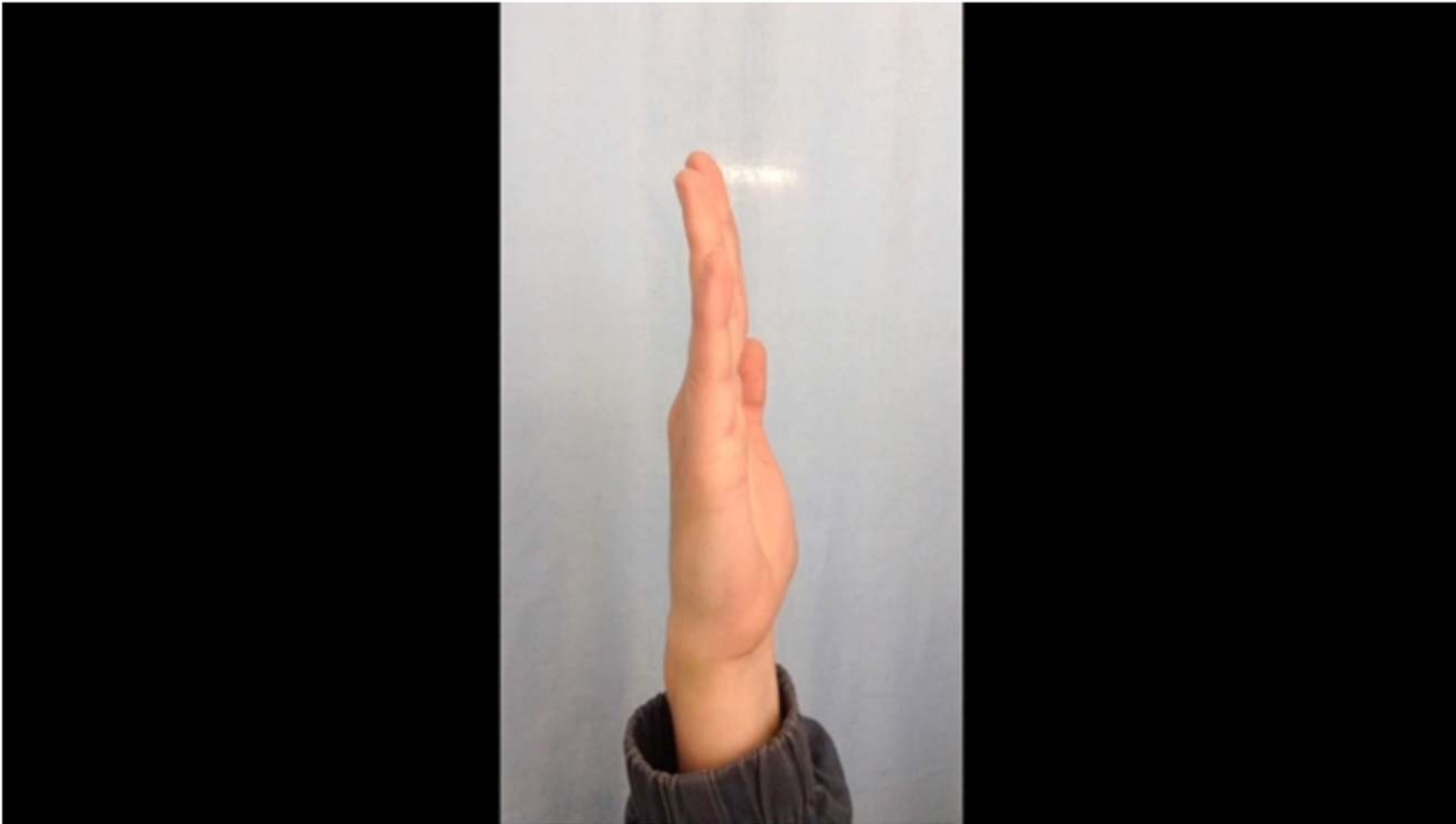Case 7

4 week flexion



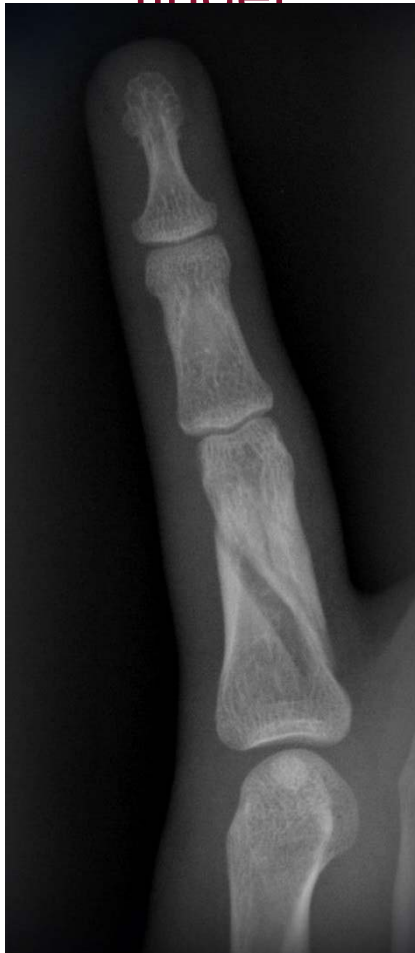Case 7

4 week AROM: video



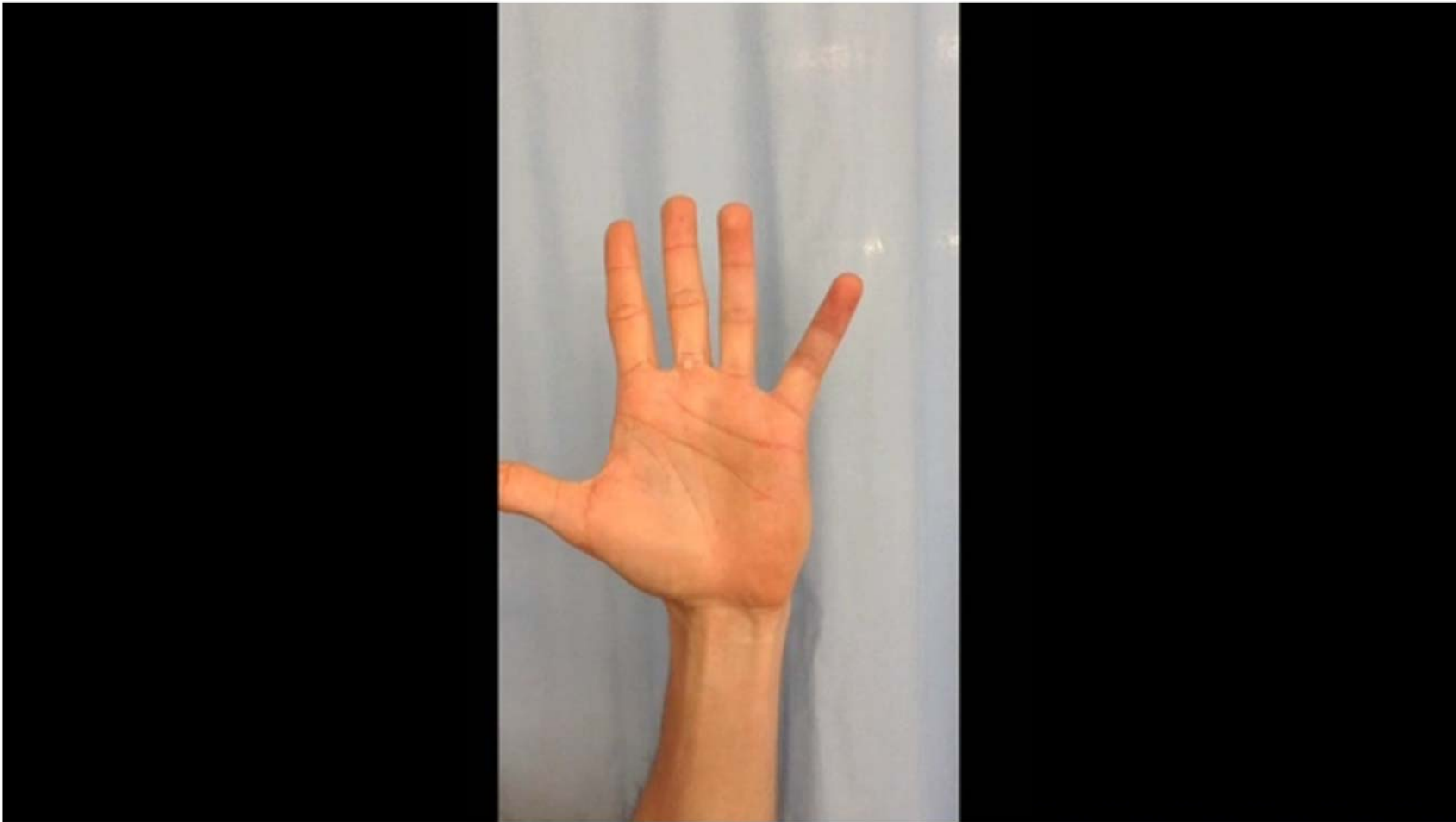Case 8

25 year old male, initial presentation, PA view, left little
finger



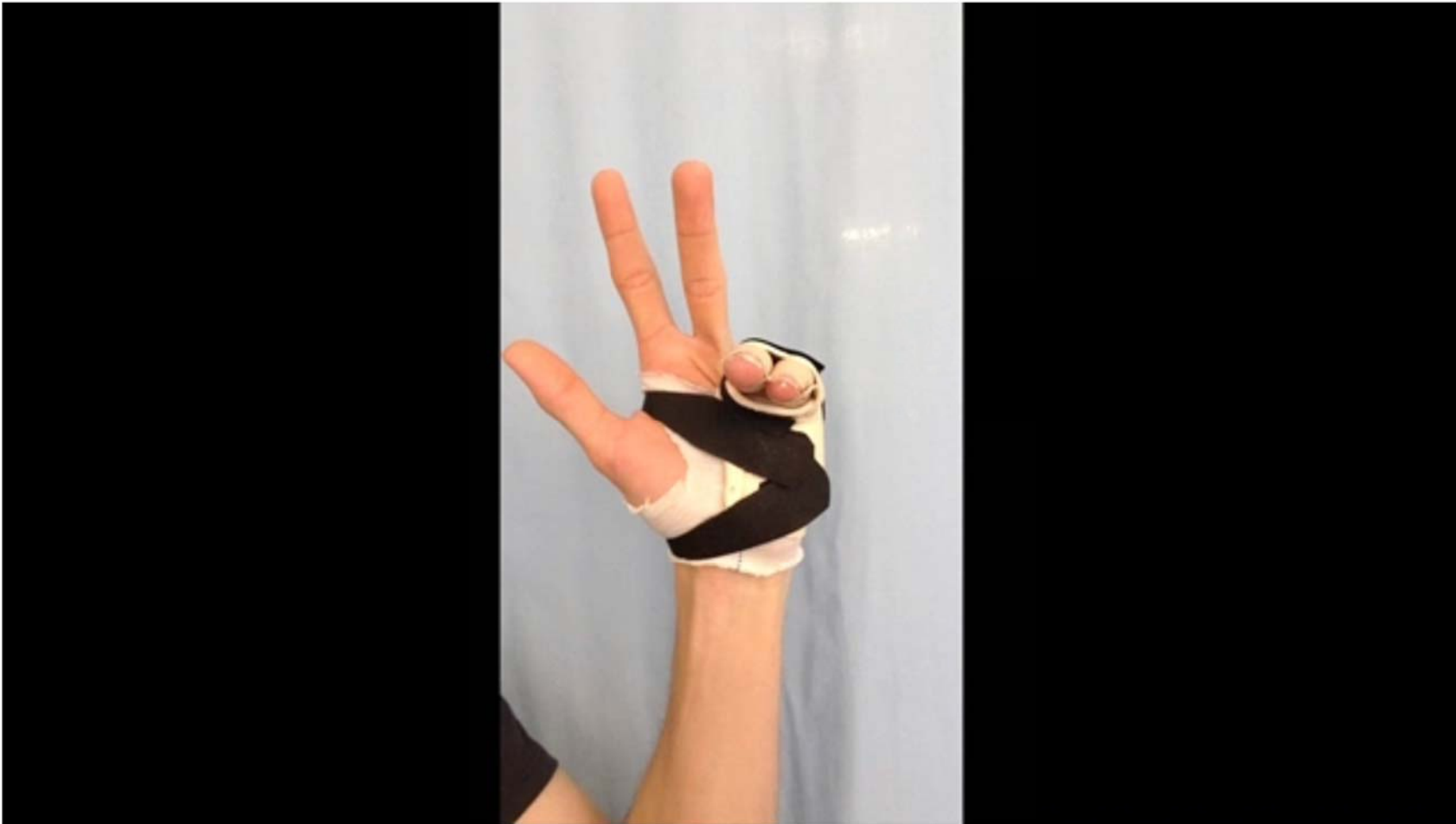Case 8

Pre reduction AROM: video



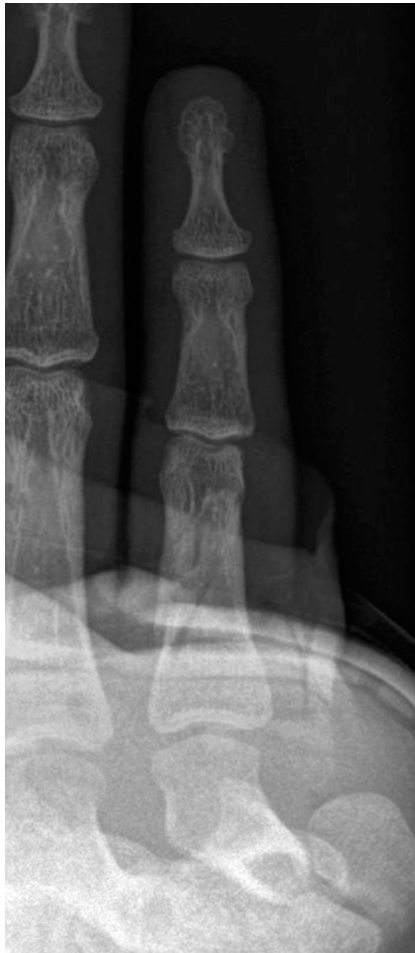Case 8

Post reduction AROM: video frontal view



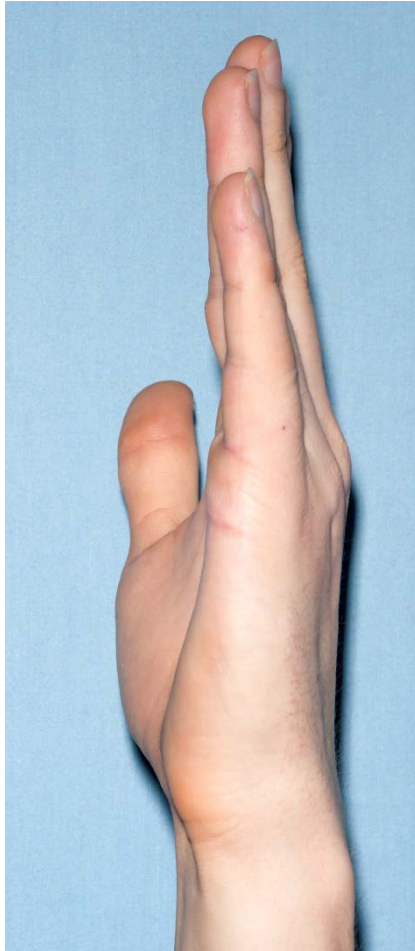Case 8

1 week post reduction, AP view



Case 8

4 week extension



Case 8

4 week flexion



