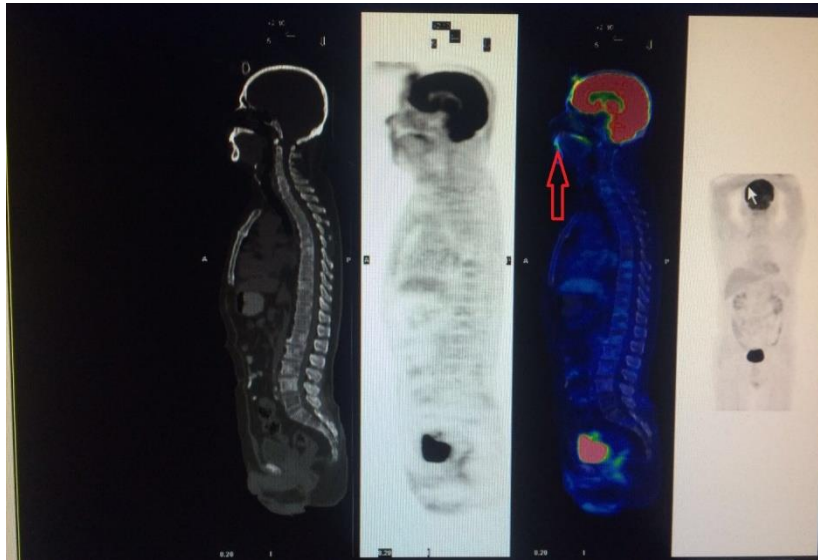


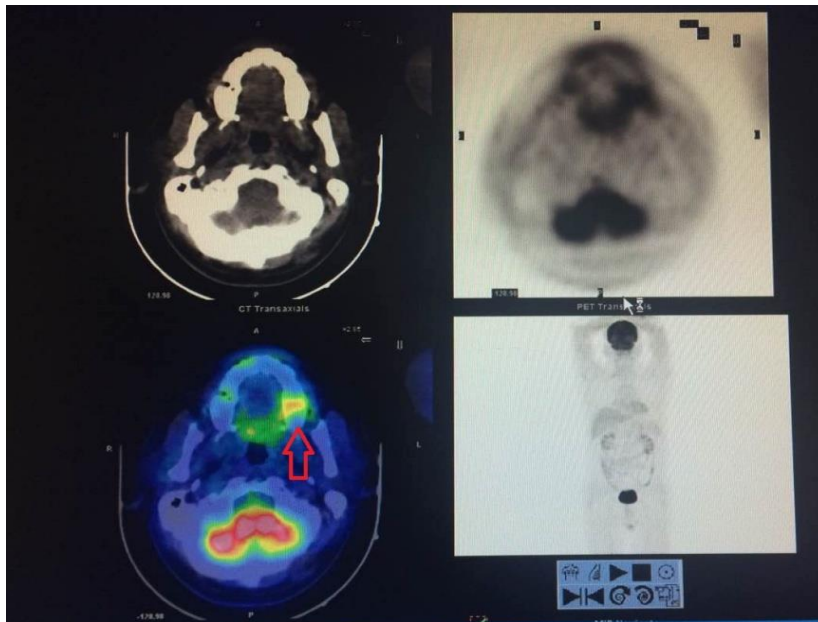
## Supplementary Figure 1 Figures of EMM lesions

Here's an example(The gums neoplasm ), Please refer to the attached "image" to see other images.

1a



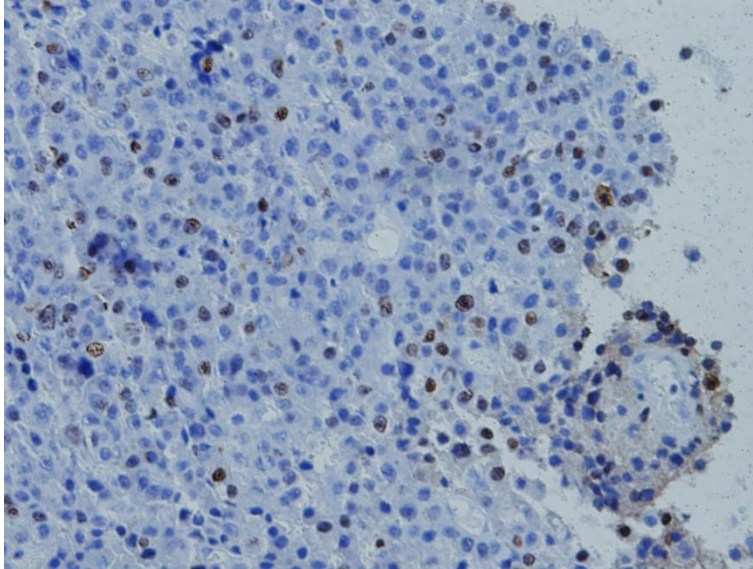
1b



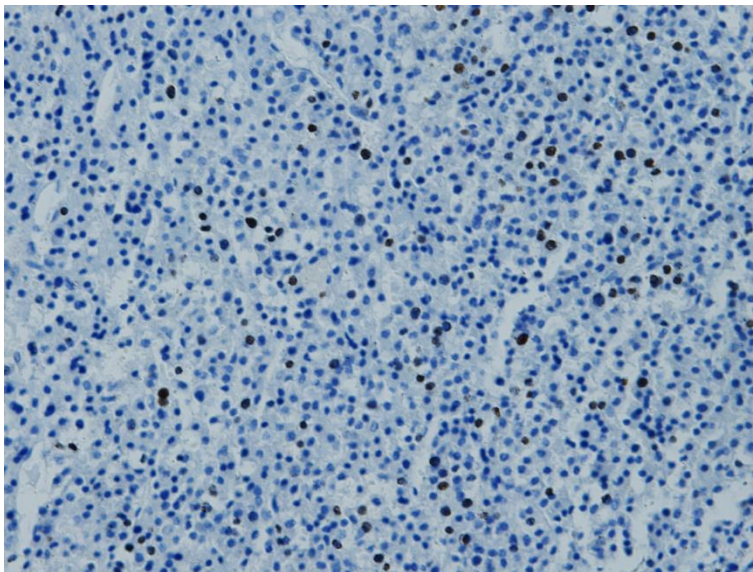
## Supplementary Figure 2 Images of staining with Ki67.

Here were some images of staining with Ki67 in extramedullary tissue.

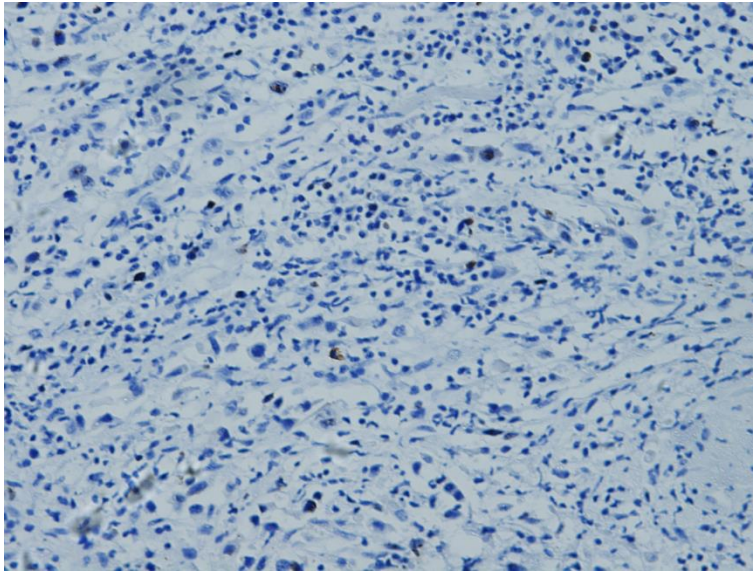
1 .20-30%



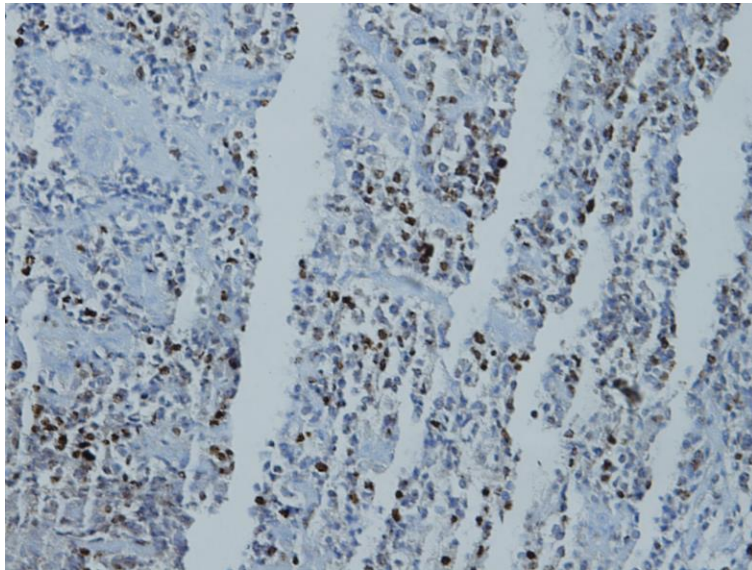
2.5-10%



3.1-5%



4.60-70%



Supplementary Table 1 The exact number of EMM lesions found in total and per patient.

Patients	EMM lesions	EMM lesions number
NO.1	left neck	1
NO.2	beside of the sacrum	1
NO.3	beside the thoracic	1
NO.4	beside the ribs	1
NO.5	chest, right neck	2
NO.6	beside the ribs	1
NO.7	chest	1
NO.8	beside the ribs	1
NO.9	gum	1
NO.10	beside the lumbar spine	1
NO.11	beside the lumbar spine	1
NO.12	Lung	1
NO.13	Kidney	1
NO.14	beside of the sacrum	1
NO.15	beside the lumbar spine	1
NO.16	liver	1
NO.17	Under the right jaw	1
NO.18	beside the ribs	1
NO.19	beside the thoracic	1
NO.20	beside the lumbar spine	1